

Open Access Article

Strategic Approach for Diabetes Mellitus Type 2 Patients with Acute Limb Ischemia and COVID-19: Is Amputation Mandatory? Case Series

Bagus Aulia Mahdi¹, Satyawardhana¹, Hermina Novida^{1*}, Agil Al Jufri², Muhammad Zulfadly Nuralim², Dhihinitia Jiwangga², Arif Rachman²

¹ Department of Internal Medicine, Faculty of Medicine, Universitas Airlangga, Dr. Soetomo General Teaching Hospital, Surabaya, Indonesia

² Department of Thoracic, Cardiac, and Vascular Surgery, Faculty of Medicine, Universitas Airlangga, General Teaching Hospital Dr. Soetomo, Surabaya, Indonesia

Abstract: Diabetes Mellitus Type 2 in COVID-19 patients accompanied by acute limb injury makes the treatment more complex. The aim of this case report is to describe the best treatment strategy for patients with diabetes mellitus type 2 with acute limb ischemia. We present two cases of patients who tested positive for COVID-19 by nasopharyngeal swab with a history of diabetes mellitus type 2, with clinical signs of acute limb ischemia. Occlusion sites of the arteries were confirmed by CT angiography in the first case, and by Doppler vascular ultrasound in the second case. Nonetheless, despite the revascularization, fine blood sugar control, and controlled COVID-19 management, amputation had to be performed since the previous attempts at treatment produced unsatisfactory results. An improvement of clinical condition after amputation was reported. Diabetes mellitus type 2 accompanied with acute limb ischemia and COVID-19 is a complex case that needs good hyperglycemic control management, comprehensive COVID-19 treatment, and immediate treatment for acute limb ischemia. Revascularization strategy appears to be insufficient, and all clinical and laboratory aspects showed promising improvement following the amputation.

Keywords: diabetes mellitus, acute limb ischemia, COVID-19, revascularization, amputation.

患有急性肢体缺血和新冠肺炎的 2 型糖尿病患者的战略方法：截肢是强制性的吗？ 案例系列

摘要：伴有急性肢体损伤的新冠肺炎患者的 2 型糖尿病使治疗更加复杂。本病例报告的目的是描述患有急性肢体缺血的 2 型糖尿病患者的最佳治疗策略。我们介绍了两例通过鼻咽拭子检测出新冠肺炎阳性的患者，这些患者有 2 型糖尿病病史，具有急性肢体缺血的临床症状。动脉闭塞部位在第一个病例中通过计算机断层扫描血管造影确认，在第二个病例中通过多普勒血管超声确认。尽管如此，尽管进行了血运重建、良好的血糖控制和受控的新冠肺炎管理，但由于先前的治疗尝试产生了不令人满意的结果，因此必须进行截肢。据报道，截肢后临床状况有所改善。伴有急性肢体缺血和新冠肺炎的 2 型糖尿病是一个复杂的病例，需要良好的高血糖控制管理、全面的新冠肺炎治疗以及急性肢体缺血的即时治疗。血运重建策略似乎是不够的，截肢后所有临床和实验室方面都显示出有希望的改善。

关键词：糖尿病、急性肢体缺血、新冠肺炎、血运重建、截肢。

Received: April 16, 2021 / Revised: May 17, 2021 / Accepted: June 15, 2021 / Published: July 31, 2021

About the authors: Bagus Aulia Mahdi, Satyawardhana, Hermina Novida, Department of Internal Medicine, Faculty of Medicine, Universitas Airlangga, Dr. Soetomo General Teaching Hospital, Surabaya, Indonesia; Agil Al Jufri, Muhammad Zulfadly Nuralim, Dhihinitia Jiwangga, Arif Rachman, Department of Thoracic, Cardiac, and Vascular Surgery, Faculty of Medicine, Universitas Airlangga, General Teaching Hospital Dr. Soetomo, Surabaya, Indonesia

Corresponding author Hermina Novida, hermina-n@fk.unair.ac.id

1. Introduction

Diabetes mellitus type 2 (DMT2) is one of the highest comorbidities found in COVID-19 patients. People with diabetes mellitus type 2 (DMT2) are two to four times more prone to severe acute respiratory syndrome - coronavirus type 2 (SARS CoV-2) and have twice the mortality rate than non-DMT2 patients when infected by the virus. This could be the reason for the high comorbidity of DMT2 found in COVID-19 patients [1, 2].

Acute limb ischemia (ALI) is an acute complication of peripheral arterial disease (PAD) which can occur within two weeks after decreased perfusion in the lower limbs, and amputation risk is often inevitable. Acute limb ischemia is a critical condition with high mortality and morbidity events. Peripheral arterial disease in a patient with DMT2 has four times the risk of becoming critical limb ischemia (CLI) than in non-DMT2 patients. Poor glycemic control will further exacerbate the ALI and could lead to amputation [3].

Hypercoagulopathy causing thrombosis occurred in COVID-19 patients. A clinical implication of this condition is that the high rates of thrombotic events may increase the incidence of ALI. COVID-19 with ALI could lead to sepsis and multiple organ failure, which results in higher mortality events. Diabetes mellitus type 2 with ALI and COVID-19 is a complicated case and requires comprehensive treatment. So far, there is little knowledge about the optimal management of this case, as DMT2 accompanied with COVID-19 has distinct clinicopathological features from other systemic coagulopathies associated with severe infection [3, 4]. An effective management strategy for this case, based on several case reports and studies, are still unclear. Our case report will discuss the best treatment approach for DMT2 patients with ALI and COVID-19.

2. Clinical Case 1

A 55-year-old woman with a medical history of type 2 diabetes mellitus presented to the emergency room (ER) of Dr. Soetomo Hospital on July 18th, 2020. She complained of occasional pain and coldness in her right foot, and that the toes on that foot had turned black. They appeared with erythema that had extended to the proximal toes in the past 3 days. One week before she came to the ER, she only felt numbness and a tingling sensation in the foot along with fever, cough, and dyspnea. She felt pain and cramps while walking, but the pain was relieved with rest. She did not complain of nausea and vomiting, diarrhea, or anosmia. She took

paracetamol three times daily for three days to relieve the pain in the right foot (Fig. 1).

Her blood pressure (BP) was 100/75 mmHg, pulse (P) was 105/minute, respiration rate (RR) was 24/minute, O₂ saturation (SaO₂) was 92% free air, 95% with a non-rebreathing mask 10 lpm, and temperature (T) was 36.7°C. The pulse of the right a. femoralis was palpable bilaterally, unpalpable in the right a. poplitea, a. tibialis posterior, and a. dorsalis pedis, and capillary refill time (CRT) was less than 2 seconds, ankle-brachial index was 0.9, SaO₂ in the right toes was undetected, and SaO₂ in the left toes was 97%.

A laboratory examination in the ER showed hemoglobin (Hb) was 14.3 g/dl, hematocrit was 42.5%, white blood count was 19.28 x 10³ /uL, platelets were 318.000/uL. Neutrophil (Neu) was 88.1%, lymphocyte (Lymp) was 6.1% (Neutrophil-Lymphocyte Ratio/NLR 14.42). Albumin was 2.85 mg/dl, SGOT 122 U/L SGPT 136 U/L Blood Glucose (BG) was 371 mg/dl, HbA1c was 10.2%, APPT was 20.6 seconds, PPT was 10.6 seconds, and INR was 2.47. D-dimer was 10.650 mcg/L, LDH was 658 U/L. Fibrinogen was 727.2 mg/dl. The blood gas analysis (BGA) result showed pH was 7.46, pCO₂ was 24 mmHg, pO₂ was 51 mmHg, HCO₃ was 17.1 mmol/L, BE was -6.7, SaO₂ was 88%, FiO₂ was 21%, and PaO₂:FiO₂ ratio (P/F ratio) was 255. Both rapid antibody COVID-19 and PCR swab tests were positive.

Chest x-ray examination (CXR) on July 18, 2020 showed homogenous, peripheral consolidation on both lungs and cardiomegaly, concluded to be bilateral pneumonia and aortosclerosis. A CT-angiography showed total occlusion in the right femoral is artery, levelling distal femur distant to the distal right artery femoral is communis +/-25.4 cm and distant to the bifurcatio aortae +/-43.1 cm, and no blood flow in the distal artery (Fig. 2).

The patient was diagnosed with pneumonia COVID-19, acute limb ischemia Rutherford IIb, acute respiratory distress syndrome, and diabetes mellitus type 2. She underwent immediate salvage limb treatment for revascularization by thrombectomy (Fig. 3). Her condition worsened on the sixth day after thrombectomy, even though she was treated with basal-bolus correction for hyperglycemia control and heparinization with an antiviral and an anticoagulant for COVID-19 management.

She was transferred to the ICU, and an amputation was performed (Fig. 3). After receiving intensive treatment for 10 days, she began to gradually improve, and her glyemic profile was under control (Fig. 4). She was discharged from the hospital after 24 days of hospitalization.

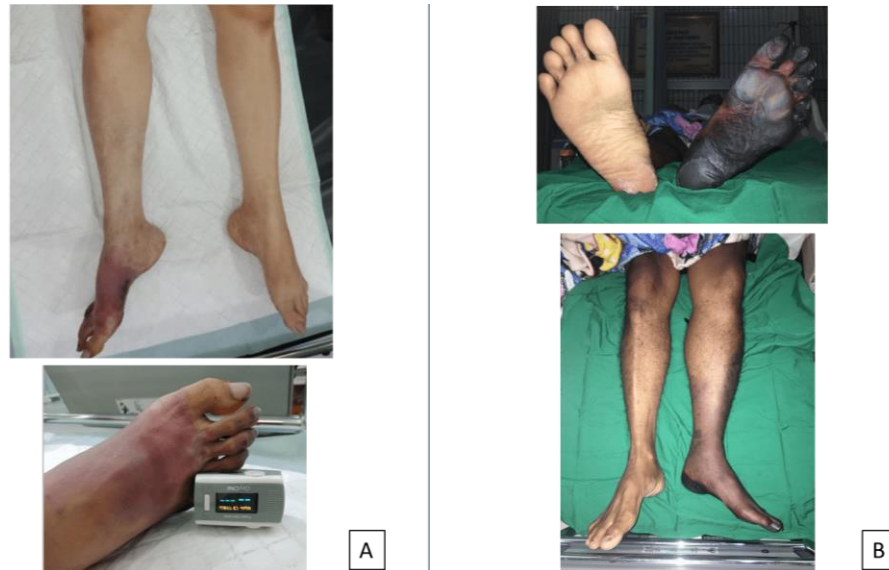

Fig. 1. Initial right foot appearance in Emergency Room: (A) the first case, (B) the second case

Laboratory and Radiology Examination from ER					
Hb	14,3	Neu	88,1	Rapid Test	Reactive
Wbc	19,280	Limf	6,1	Swab PCR	+
PLT	318.000	NLR	14,4		
BUN	10	Na	126	D-dimer	10.650
SCr	0,4	K	3,9	Fibrinogen	727,7
Alb	2,85	Cl	91	APTT	20,6
SGOT	122	GDA	371	PPT	10,6
SGPT	136	HbA1c	10,2%	INR	2,47
				BGA	
				pH	7,46
				pCO ₂	24
				pO ₂	51
				HCO ₃	17,1
				BE	-6,7
				FiO ₂	21%
				P/F ratio	255
Chest X Ray	showed homogeny consolidation bilateral peripheral lung, cor cardiomegaly, concluded pneumonia bilateral and aortosclerosis.				
CTA	total occlusion in right artery femoralis, leveling distal femur distance to distal right artery femoralis coumnnis +/- 25,4 cm and distance to bifurcatio aorta +/- 43,1 cm, and unseen run in distal artery				
Dx	pneumonia COVID-19 confirmed acute limb ischemia, acute respiratory distress syndrome, diabetes mellitus type 2, hyponatremia hypotonic hypovolemic, hypoalbumin, and hepatitis reactive non-specific.				

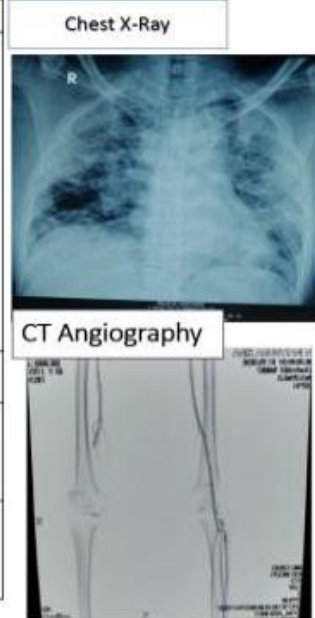


Fig. 2 Laboratory and radiology findings of the patient's in the first case

3. Clinical Case 2

A 67-year-old man with a medical history of diabetes mellitus type 2 presented to the emergency room (ER) of a private hospital on January 29, 2021. He complained of pain, cold, and numbness in the lower left extremity for one week along with a mild cough and shortness of breath. He had received medicine from his company physician, but there had been no improvement (Fig. 1B). He routinely took Metformin 500 mg three times daily and glimepiride 2 mg daily. He was a smoker. The patient's company doctor had prescribed heparin 900IU/hr for 10 days, but there was no improvement, so he was transferred to our hospital (DR Soetomo General Hospital).

The patient's BP was 116/70 mmHg, his pulse (P) was 91/minute, his respiration rate (RR) was 22/minute, his O₂ saturation (SaO₂) was 91% free air and 99% with a non-rebreathing mask, and his temperature (T) was 36.8°C. An examination of his left

lower extremity showed no palpable pulse in the left a. dorsalis pedis, a. tibialis posterior, and a. poplitea, and a weak pulse in the left a. formalis. There was a loss of sensory function extending to below the knee with loss of motor function. Necrotic tissue was identified from the sole up to below the knee (Fig. 1). Laboratory examination in the ER showed haemoglobin (Hb) 10.8 g/dl, Hct 32.5%, white blood cell 17.6 x 10³ /uL, platelets 174.000/uL, neutrophil 87.3%, and lymphocyte 6.2%. (neutrophil-lymphocyte ratio/NLR: 14.08). Further tests showed albumin 2.95 mg/dl, AST 123 U/L ALT 97 U/L, blood glucose (BG) 141 mg/dl, HbA1c 9.2%, APPT 35.3 seconds and PPT 15.2 seconds, INR 2.45. D-dimer 3.260 mcg/L, and fibrinogen 827.2 mg/dl. Blood gas analysis (BGA) showed pH 7.46, pCO₂ 35 mmHg, pO₂ 58 mmHg, HCO₃ 24.9 mmol/L, BE 1.1, SaO₂ 91%, FiO₂ 21%, PaO₂:FiO₂ ratio (P/F ratio 290). Both rapid COVID-19 antibody and PCR swab tests were positive.

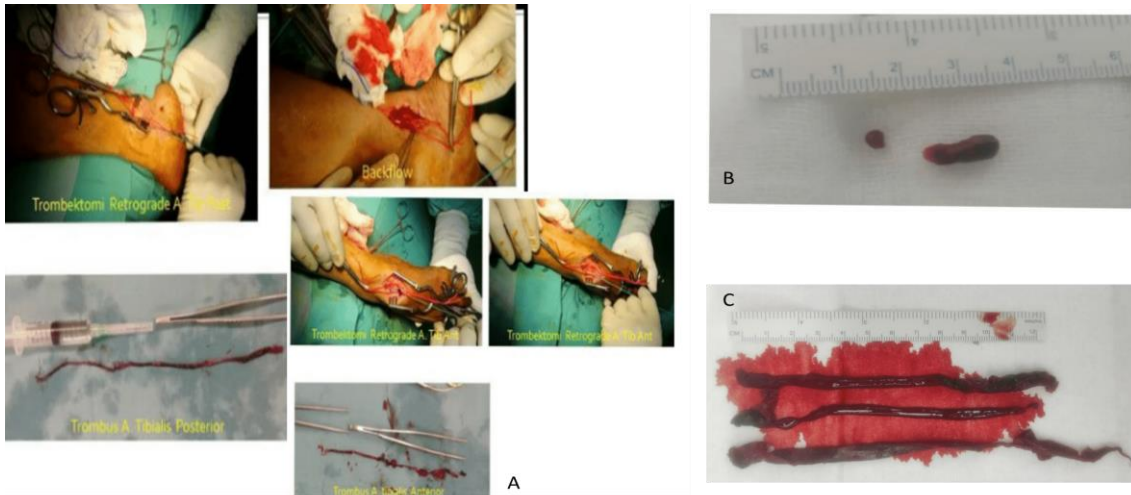


Fig. 3 (A) Thrombus in thrombectomy in the first case; (B) Thrombus finding in amputation surgery in the first case; (C) Thrombus finding in amputation surgery in the second case

A chest x-ray examination on January 29, 2021 showed patchy consolidation in the left and right parcardial homogeneity, concluded to be bilateral pneumonia and aortosclerosis. A Doppler vascular ultrasound test showed loss of pulsation in the left a. dorsalis pedis, a. tibialis posterior, and a. poplitea and normal pulsation in the right a. dorsalis pedis, a. tibialis posterior, and a. poplitea.

The patient was diagnosed with COVID-19 pneumonia, acute limb ischemia Rutherford III, acute respiratory distress syndrome, and diabetes mellitus type 2. An urgent revascularization with thrombectomy and amputation was performed to save life (Fig. 3).

After the amputation, the patient was transferred to the COVID-19 isolation ward. During the first week, his respiration improved, and he tested negative twice for COVID-19, so he was transferred to a non-isolation ward. An oral anticoagulant was given to the patient after the amputation to retain vascular patency. The patient complained of pain at the site of the operation, but the pain gradually lessened during the first week. After receiving intensive treatment for 13 days, he was gradually improving, and his glycaemic profile was good with short-acting insulin. He was discharged from the hospital after 13 days of hospitalization.

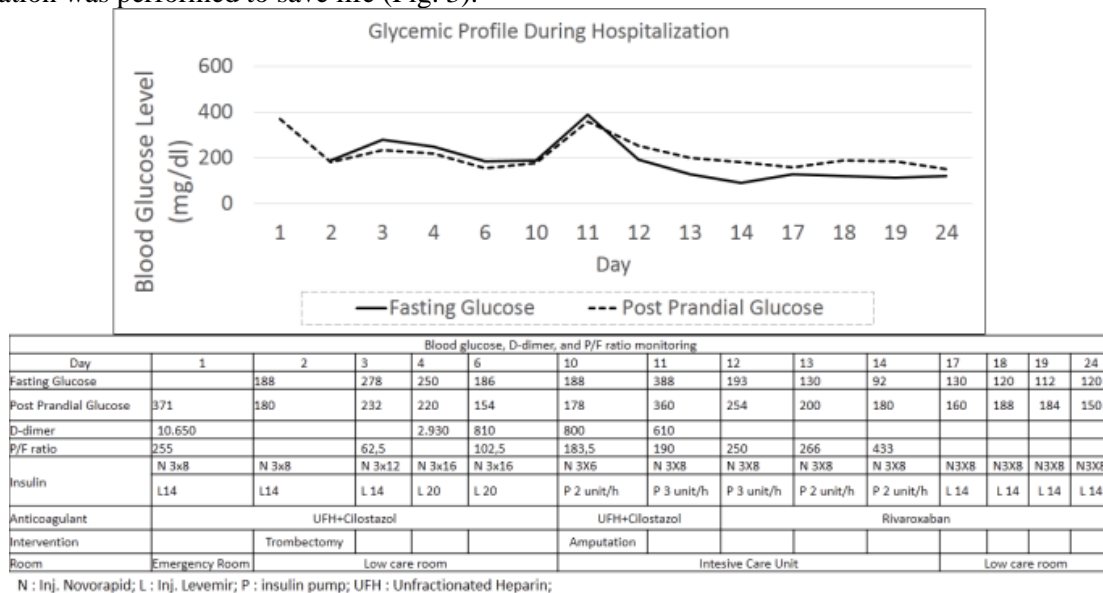


Fig. 4 Glycemic control profile during hospitalization from the first case

4. Discussion

Uncontrolled hyperglycemia during the COVID-19 pandemic worsened the condition of DM type 2 patients with COVID-19. Therefore, effective glycaemic control is mandatory. The glycaemic control target for critical conditions in the ICU is generally 140–180 mg/dl. The method used to control hyperglycaemia in

critically ill patients should be based on the patient’s clinical condition. If the patient is hemodynamically unstable, has unstable insulin requirements and parenteral nutrition, and uses a corticosteroid, the recommended therapy is correction by continuous intravenous insulin infusion with hourly monitoring of blood glucose. If the critically ill patient is

hemodynamically stable, has stable insulin requirements, and uses subcutaneous insulin, basal correction or basal-bolus correction can be administered with blood glucose evaluation every 4–6 hours. Hyperglycaemic control for non-critically ill patients (glycemia > 180 mg/dl at admission) may use basal-bolus insulin with monitoring of blood glucose before meals and at bedtime [5].

COVID-19 is a disease that provokes a hypercoagulable state, making patients with DM type 2 more susceptible to CLI, resulting in an increasing incidence of ALI. A process of cell disruption is caused by virus infiltration, leading to a disseminated intravascular coagulopathy (DIC)-like clinical picture, where D-dimer and fibrin/fibrinogen breakdown products are significantly elevated, and microvascular microthrombi are formed. Modalities currently being used to assess the hypercoagulable state of COVID-19 patients include thromboelastography (TEG) and rotational thromboelastometry (ROTEM). TEG findings have shown shortened R (increased thrombin burst), shortened K (increased fibrin generation), increased MA (greater clot strength), and reduced LY30 (reduced fibrinolysis). Other findings of a hypercoagulable state have been elevated vWFactor VII, increased D-dimer, elevated fibrinogen, neutrophil extracellular traps, and prothrombotic microparticles and anionic phospholipids [6–9].

Acute limb ischemia (ALI) can be classified into the following categories: category I refers to viable limbs that are not immediately threatened; category II refers to threatened limbs; category IIa is when limbs are marginally threatened and salvageable, if promptly treated; category IIb refers to immediately threatened limbs that require immediate revascularization if salvage is to be accomplished; and category III refers to irreversibly damaged limbs, in which case resultant major tissue loss or permanent nerve damage is inevitable. Revascularization modality is recommended for category IIa (slow to intact capillary refill time, sensory loss limited to toe, no muscle weakness) and category IIb (slow to absent capillary refill time, sensory loss more than toes with rest pain, and mild to moderate muscle weakness). Pharmacotherapy for the patient with PAD includes antiplatelet, statin agents, anti-hypertensive, anticoagulant, smoking cessation, glycaemic control, cilostazol, pentoxifylline, and chelation therapy. When limb salvage therapy by revascularization could not improve the condition, amputation is the last resort [10–13].

The optimal management for COVID-19 has not been established until today. Nevertheless, the use of several antivirals like lopinavir/ritonavir, oseltamivir, remdesivir, favirapir is recommended. Anticoagulant treatment is mandatory for the hypercoagulable state in COVID-19, and treatment options for this condition include low molecular weight heparin (LMWH) or

unfractionated heparin (UFH). As anticoagulants, UFH and LMWH have been proven to have anti-inflammatory effects by suppressing IL-6 and IL-8 expression from epithelial cells in the lung, preventing hyperinflammation condition and thrombotic complications associated with cytokine storm in COVID-19 [6, 14]. In our case, we know that thrombus from ALI and COVID-19 was so massive that it was difficult to treat.

The prognosis of acute limb ischemia following diabetes mellitus type 2 and COVID-19 was worse than diabetes mellitus type 2 only without COVID-19 and included a high mortality rate. Patients presenting with type 2 diabetes mellitus and COVID-19 had twice the rate of non-type-2-DM patients. Acute limb ischemia during COVID-19 infection was reported from several case reports wherein patients exhibited poor clinical condition correlating to the severity of the COVID-19 infection and usually ending in death [1, 3, 4, 14, 15]. In this study, revascularization was not enough to improve clinical condition. The first patient exhibited a decent amount of improvement and was discharged after twenty-four days of hospitalization. She felt better after having the amputation and so did the second patient.

The primary limitation of this study is the sample size being only two cases due to the comorbidity of ALI, type 2 diabetes mellitus, and COVID-19 being a rare case. We recommend a case review from several case reports around the world in order to comprehensively consider the clinical presentation, treatment, and management of ALI, DMT2, and COVID-19.

5. Conclusion

Type 2 Diabetes mellitus accompanied with COVID-19 and ALI is a complex case. It requires good management of glycemic control, comprehensive COVID-19 treatment, and immediate salvage limb treatment. The hyperinflammation and hypercoagulopathy presented in COVID-19 can induce the ARDS. Revascularization seems to inadequately improve clinical condition due to massive thrombus production, which makes amputation inevitable. The prognosis for type 2 DM with ALI and COVID-19 is worse than in other patients and most cases ended with death. However, our two cases showed a good result after amputation was performed.

References

- [1] AGGARWAL G., LIPPI G., LAVIE C. J., HENRY B. M., and SANCHIS-GOMAR F. Diabetes Mellitus Association with Coronavirus Disease 2019 (COVID-19) Severity and Mortality: A Pooled Analysis. *Journal of Diabetes*, 2020, 12(11): 851-855. <https://doi.org/10.1111/1753-0407.13091>
- [2] PARVEEN R., SEHAR N., BAJPAI R., and AGARWAL N. B. Association of diabetes and hypertension

with disease severity in COVID-19 patients: A systematic literature review and exploratory meta-analysis. *Diabetes Research and Clinical Practice*, 2020, 166: 108295. <https://doi.org/10.1016/j.diabres.2020.108295>

[3] KAUR P., QAQA F., RAMAHI A., SHAMOON Y., SINGHAL M., SHAMOON F., MAROULES M., and SINGH B. Acute upper limb ischemia in a patient with COVID-19. *Hematology/Oncology and Stem Cell Therapy*, 2020. <https://doi.org/10.1016/j.hemonc.2020.05.001>

[4] GALANIS N., STAVRAKA C., AGATHANGELIDIS F., PETSATODIS E., GIANKOULOF C., and GIVISSIS P. Coagulopathy in COVID-19 infection: a case of acute upper limb ischemia. *Journal of Surgical Case Reports*, 2020, 2020(6): rjaa204. <https://doi.org/10.1093/jscr/rjaa204>

[5] BELLIDO V., & PÉREZ A. Inpatient Hyperglycemia Management and COVID-19. *Diabetes Therapy*, 2021, 12: 121-132. <https://doi.org/10.1007/s13300-020-00966-z>

[6] KICHLOO A., DETTLOFF K., ALJADAH M., ALBOSTA M., JAMAL S., SINGH J., WANI F., KUMAR A., VALLABHANENI S., and KHAN M. Z. COVID-19 and Hypercoagulability: A Review. *Clinical and Applied Thrombosis/Hemostasis*, 2020, 26: 1-9. <https://doi.org/10.1177/1076029620962853>

[7] ABOU-ISMAIL M. Y., DIAMOND A., KAPOOR S., ARAFAH Y., and NAYAK L. The hypercoagulable state in COVID-19: Incidence, pathophysiology, and management. *Thrombosis Research*, 2020, 194: 101-115. <https://doi.org/10.1016/j.thromres.2020.06.029>

[8] RAJPAL A., RAHIMI L., and ISMAIL-BEIGI F. Factors Leading to High Morbidity and Mortality of COVID-19 in Patients with Type 2 Diabetes. *Journal of Diabetes*, 2020, 12(12): 895-908. <https://doi.org/10.1111/1753-0407.13085>

[9] SINGHANIA N., BANSAL S., NIMMATOORI D. P., EJAZ A. A., MCCULLOUGH P. A., and SINGHANIA G. Current Overview on Hypercoagulability in COVID-19. *American Journal of Cardiovascular Drugs*, 2020, 20(5): 393-403. <https://doi.org/10.1007/s40256-020-00431-z>

[10] GERHARD-HERMAN M. D., GORNIK H. L., BARRETT C., BARSHES N. R., CORRIERE M. A., DRACHMAN D. E., FLEISHER L. A., FOWKES F. G., HAMBURG N. M., KINLAY S., LOOKSTEIN R., MISRA S., MUREEBE L., OLIN J. W., PATEL R. A., REGENSTEINER J. G., SCHANZER A., SHISHEBOR M. H., STEWART K. J., TREAT-JACOBSON D., and WALSH M. E. 2016 AHA/ACC Guideline on the Management of Patients With Lower Extremity Peripheral Artery Disease: Executive Summary: A Report of the American College of Cardiology/American Heart Association Task Force on Clinical Practice Guidelines. *Circulation*, 2017, 135(12): e686-e725. <https://doi.org/10.1161/CIR.0000000000000470>

[11] OLINIC D.-M., STANEK A., TĂTARU D.-A., HOMORODEAN C., and OLINIC M. Acute Limb Ischemia: An Update on Diagnosis and Management. *Journal of Clinical Medicine*, 2019, 8(8): 1215. <https://doi.org/10.3390/jcm8081215>

[12] FUKUDA I., CHIYOYA M., TANIGUCHI S., and FUKUDA W. Acute limb ischemia: contemporary approach. *General Thoracic and Cardiovascular Surgery*, 2015, 63(10): 540-548. <https://doi.org/10.1007/s11748-015-0574-3>

[13] GILL P., SILVERMAN S., BENNETT P., and LIP G. Peripheral arterial disease and Virchow's triad. *Thrombosis and Haemostasis*, 2017, 101(6): 1032-1040. <https://doi.org/10.1160/TH08-08-0518>

[14] BACCELLIERI D., BILMAN V., APRUZZI L., MONACO F., D'ANGELO A., LOSCHI D., MELISSANO G., and CHIESA R. A Case of Covid-19 Patient with Acute Limb Ischemia and Heparin Resistance. *Annals of Vascular Surgery*, 2020, 68: 88-92. <https://doi.org/10.1016/j.avsg.2020.06.046>

[15] KAUR P., POSIMREDDY S., SINGH B., QAQA F., HABIB H. A., MAROULES M., and SHAMOON F. COVID-19 Presenting as Acute Limb Ischaemia. *European Journal of Case Reports in Internal Medicine*, 2020, 7(6). https://doi.org/10.12890/2020_001724

参考文献:

[1] AGGARWAL G., LIPPI G., LAVIE C. J., HENRY B. M. 和 SANCHIS-GOMAR F. 糖尿病与 2019 年冠状病毒病 (新冠肺炎) 的严重程度和死亡率: 汇总分析。糖尿病杂志, 2020, 12(11): 851-855。 <https://doi.org/10.1111/1753-0407.13091>

[2] PARVEEN R., SEHAR N., BAJPAI R. 和 AGARWAL N. B. 新冠肺炎患者糖尿病和高血压与疾病严重程度的关联: 系统文献综述和探索性荟萃分析。糖尿病研究和临床实践, 2020, 166: 108295。 <https://doi.org/10.1016/j.diabres.2020.108295>

[3] KAUR P., QAQA F., RAMAHI A., SHAMOON Y., SINGHAL M., SHAMOON F., MAROULES M. 和 SINGH B. 新冠肺炎患者的急性上肢缺血。血液学/肿瘤学和干细胞治疗, 2020。 <https://doi.org/10.1016/j.hemonc.2020.05.001>

[4] GALANIS N., STAVRAKA C., AGATHANGELIDIS F., PETSATODIS E., GIANKOULOF C. 和 GIVISSIS P. 新冠肺炎感染中的凝血病: 一例急性上肢缺血。外科病例报告杂志, 2020, 2020(6): rjaa204。 <https://doi.org/10.1093/jscr/rjaa204>

[5] BELLIDO V., & PÉREZ A. 住院高血糖管理和新冠肺炎。糖尿病治疗, 2021, 12: 121-132。 <https://doi.org/10.1007/s13300-020-00966-z>

[6] KICHLOO A., DETTLOFF K., ALJADAH M., ALBOSTA M., JAMAL S., SINGH J., WANI F., KUMAR A., VALLABHANENI S. 和 KHAN M. Z. 新冠肺炎和高凝状态: 回顾. 临床和应用血栓形成/止血, 2020, 26: 1-9. <https://doi.org/10.1177/1076029620962853>

[7] ABOU-ISMAIL M. Y., DIAMOND A., KAPOOR S., ARAFAH Y. 和 NAYAK L. 新冠肺炎中的高凝状态: 发病率、病理生理学和管理。血栓形成研究, 2020, 194: 101-115. <https://doi.org/10.1016/j.thromres.2020.06.029>

[8] RAJPAL A., RAHIMI L. 和 ISMAIL-BEIGI F. 导致 2 型糖尿病患者新冠肺炎高发病率和死亡率的因素。糖尿病杂志, 2020, 12(12): 895-908。 <https://doi.org/10.1111/1753-0407.13085>

[9] SINGHANIA N., BANSAL S., NIMMATOORI D. P., EJAZ A. A., MCCULLOUGH P. A. 和 SINGHANIA G. 新冠肺炎高凝状态的当前概述。美国心血管药物杂志, 2020, 20(5): 393-403。 <https://doi.org/10.1007/s40256-020-00431-z>

- [10] GERHARD-HERMAN M. D.、GORNIK H. L.、BARRETT C.、BARSHES N. R.、CORRIERE M. A.、DRACHMAN D. E.、FLEISHER L. A.、FOWKES F. G.、HAMBURG N. M.、KINLAY S.、LOOKSTEIN R.、MISRA S.、MUREEBE L.、OLIN J. W.、PATEL R. A.、REGENSTEINER J. G.、SCHANZER A.、SHISHHEHBOR M. H.、STEWART K. J.、TREAT-JACOBSON D. 和 WALSH M. E. 2016 美国心脏协会/ACC 下肢外周动脉疾病患者管理指南：执行摘要：一份报告美国心脏病学会/美国心脏协会临床实践指南工作组。流通，2017，135(12)：e686-e725。
<https://doi.org/10.1161/CIR.0000000000000470>
- [11] OLINIC D.-M.、STANEK A.、TĂTARU D.-A.、HOMORODEAN C. 和 OLINIC M. 急性肢体缺血：诊断和管理的更新。临床医学杂志，2019，8(8)：1215。
<https://doi.org/10.3390/jcm8081215>
- [12] FUKUDA I.、CHIYOYA M.、TANIGUCHI S. 和 FUKUDA W. 急性肢体缺血：当代方法。普通胸心血管外科，2015，63(10)：540-548。
<https://doi.org/10.1007/s11748-015-0574-3>
- [13] GILL P.、SILVERMAN S.、BENNETT P. 和 LIP G. 外周动脉疾病和维尔肖的三联征。血栓形成和止血，2017，101(6)：1032-1040。
<https://doi.org/10.1160/TH08-08-0518>
- [14] BACCELLIERI D.、BILMAN V.、APRUZZI L.、MONACO F.、D'ANGELO A.、LOSCHI D.、MELISSANO G. 和 CHIESA R. 一例新冠肺炎急性肢体缺血和肝素患者抵抗性。血管外科年鉴，2020，68：88-92。
<https://doi.org/10.1016/j.avsg.2020.06.046>
- [15] KAUR P.、POSIMREDDY S.、SINGH B.、QAQA F.、HABIB H. A.、MAROULES M. 和 SHAMOON F. 新冠肺炎表现为急性肢体缺血。欧洲内科病例报告杂志，2020，7(6)。
https://doi.org/10.12890/2020_001724